



MIRECC

*Mental Illness
Research,
Education and
Clinical Center*



**Post Deployment Mental Health
VISN 6**

Windows to the Brain: Axial Atlas 1

Lobes

Major Regions

Arterial Territories

Major Tracts

Katherine Taber, PhD, FANPA

MIRECC Assistant Director - Education

Research Health Scientist

W.G. "Bill" Hefner VAMC, Salisbury NC

Research Professor, Div Biomedical Sci

Edward Via College of Osteopathic Medicine

Robin Hurley, MD, FANPA

MIRECC Associate Director - Education

ACOS/Research and Education Service Line

W.G. "Bill" Hefner VAMC, Salisbury NC

Professor, Psychiatry and Radiology

Wake Forest University School of Medicine

Source: <http://www.mirecc.va.gov/visn6/Tools-Tips.asp>

Use of text, images and other content are subject to the following terms and conditions:

Fair Use Is Permitted

Fair use of copyrighted material includes the use for non-commercial educational purposes, such as teaching, scholarship, research, criticism, commentary, news reporting, and other content. Unless otherwise noted, users who wish to download or print text and image files from this Web site for such uses may do so without the VISN 6 MIRECC's express permission, provided that they comply with the following conditions:

The content may only be used for personal, educational or non-commercial purposes;

Users must always specifically cite the author(s) and source of the content every time the material is used, as they would for material from any printed work;

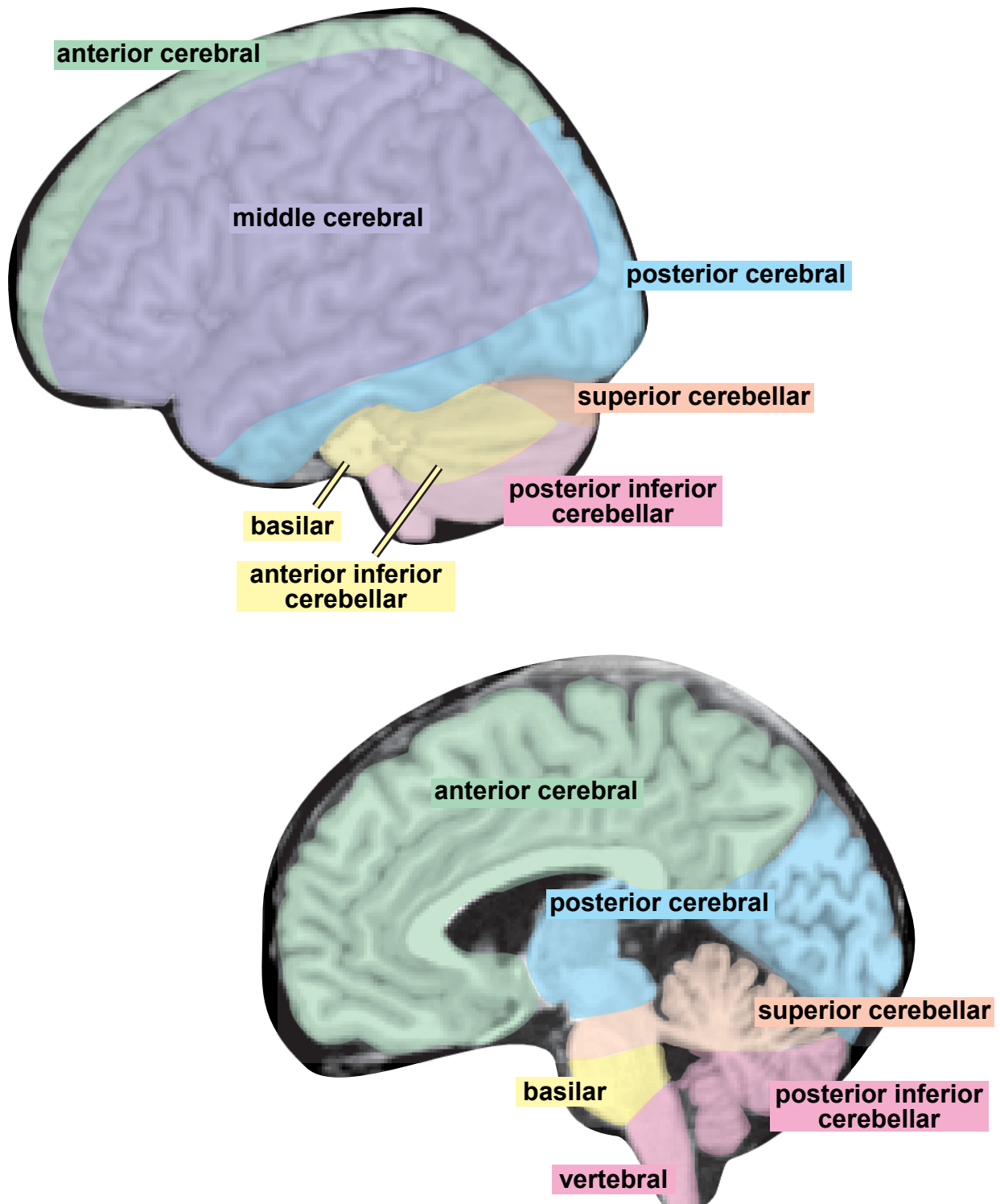
None of the content may be altered or modified.

Warranty

By downloading, printing, or otherwise using text and image files from this website, users agree and warrant that they will limit their use of such files to fair use.

Right side of each section: Arterial territories are color-coded to match the figures below.*

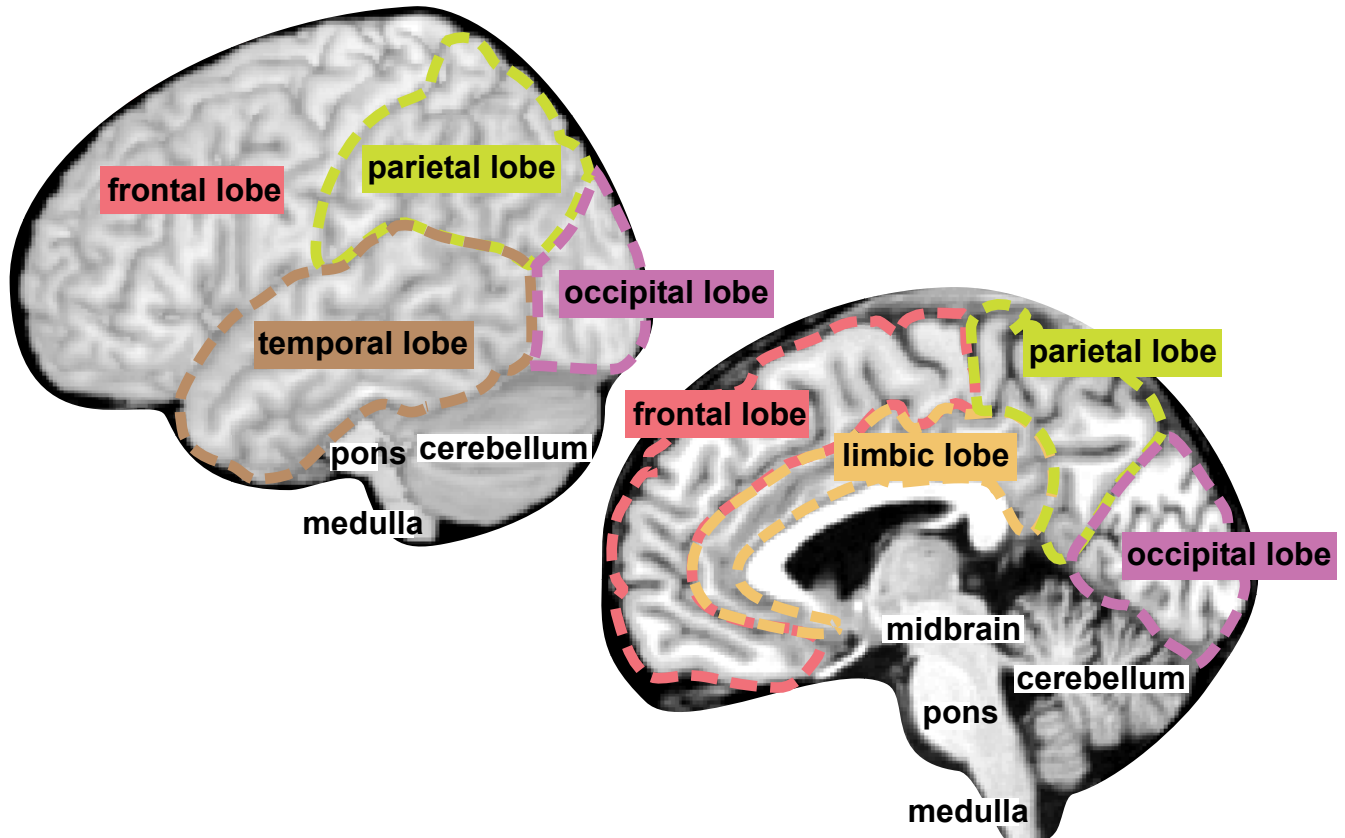
Arterial Territories



*Hurley RA, Fisher R, Taber KH. Clinical and functional imaging in neuropsychiatry. In: Yudofsky SC, Hales RE (eds). The American Psychiatric Press Textbook of Neuropsychiatry 5th Edition. American Psychiatric Press 2007: 245-300.

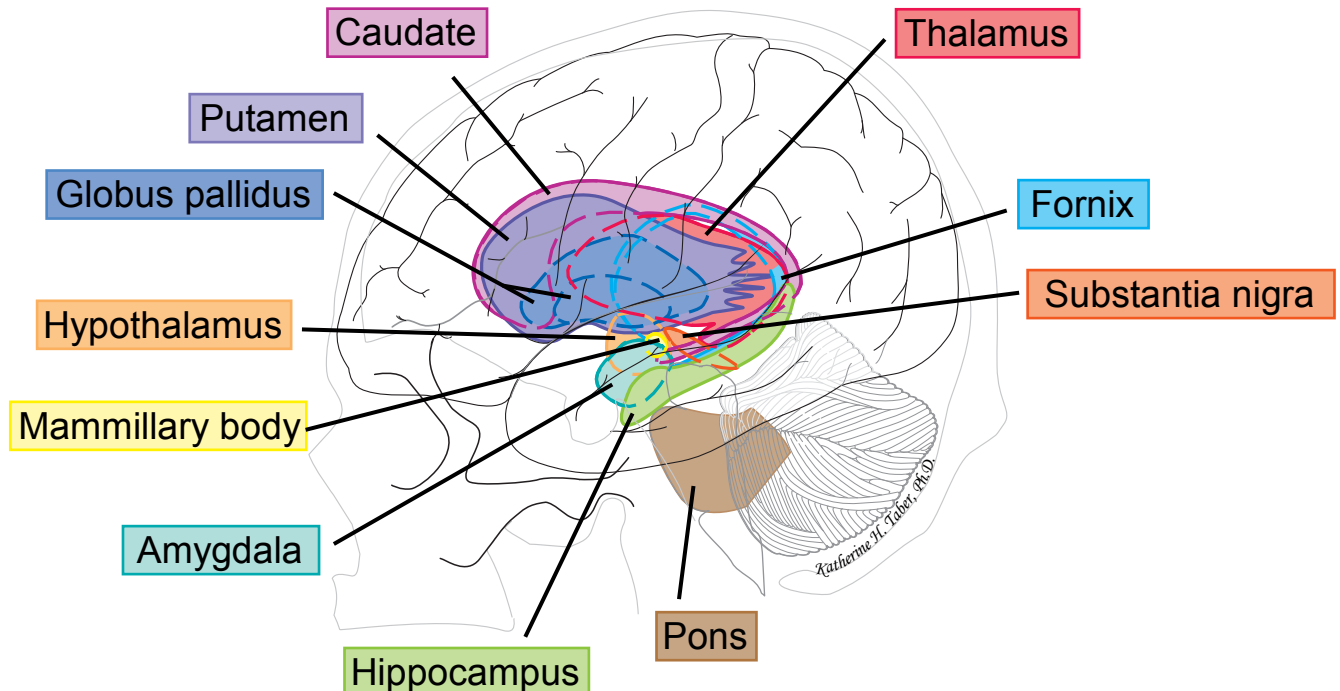
Left side of each section: Cerebral lobes, major regions, and major subcortical structures are labeled and color-coded to match the figures below.

Cerebral Lobes & Major Regions



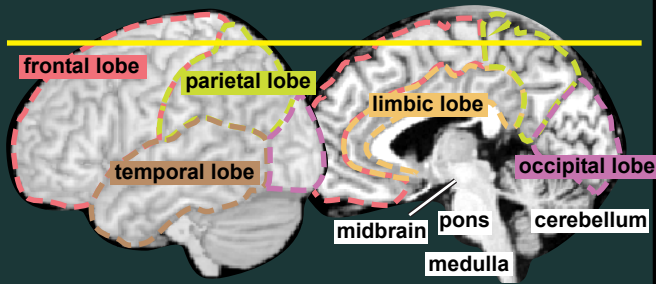
Major Subcortical Structures

This cartoon of a lateral view of the brain and skull shows the approximate positions and configurations of the major subcortical structures. The colors assigned in this figure are used in the sectional atlas to facilitate structure identification.*

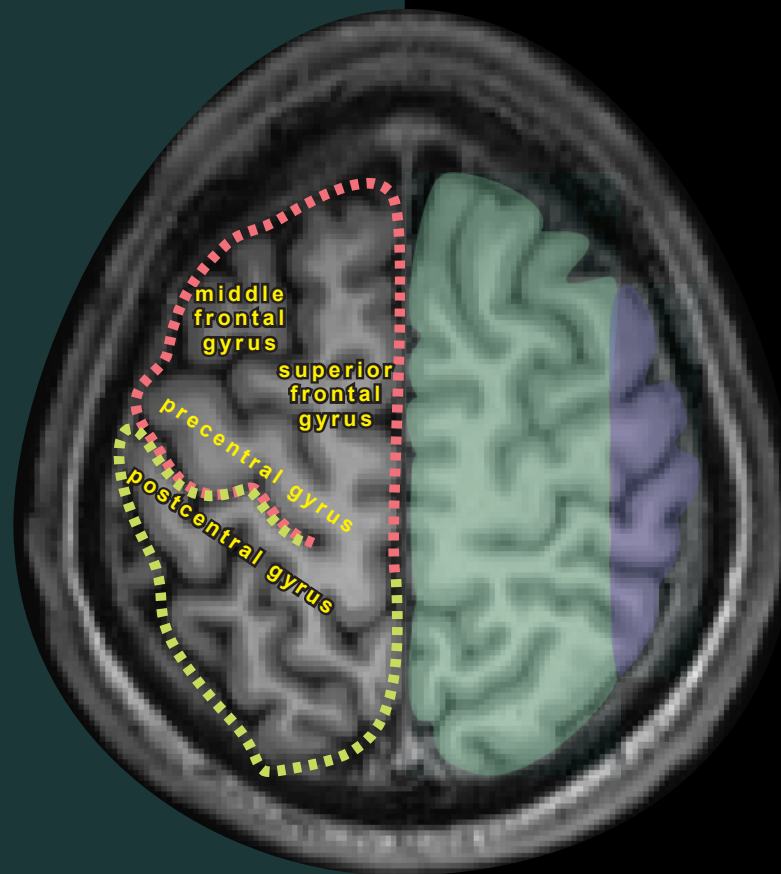
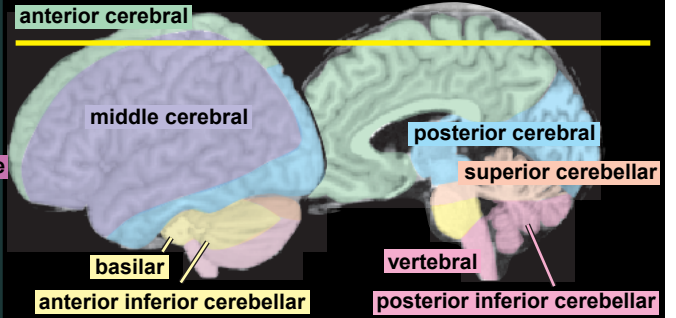


*Naumescu I, Hurley RA, Hayman LA, Taber KH. Int J Neuroradiol 1999; 5(1): 51-59.

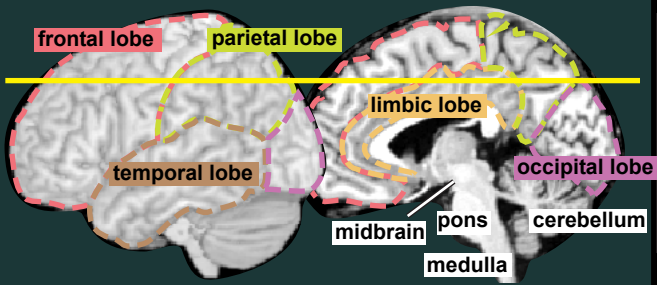
Cerebral Lobes & Major Regions



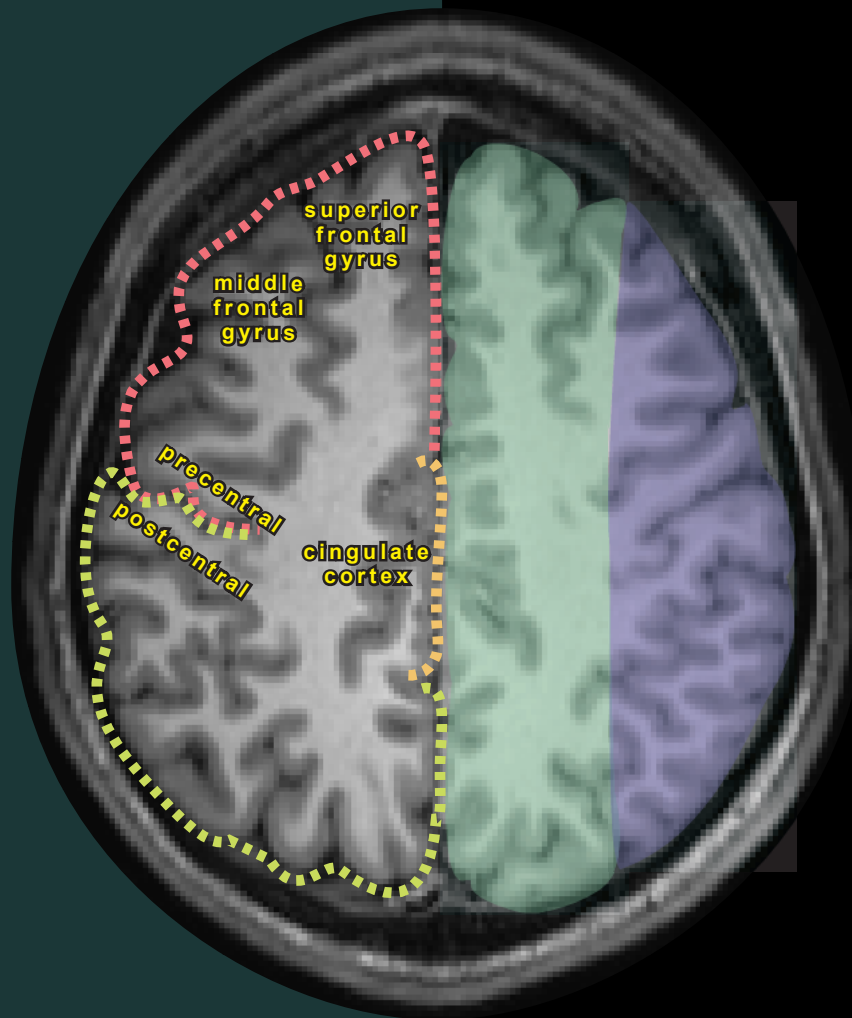
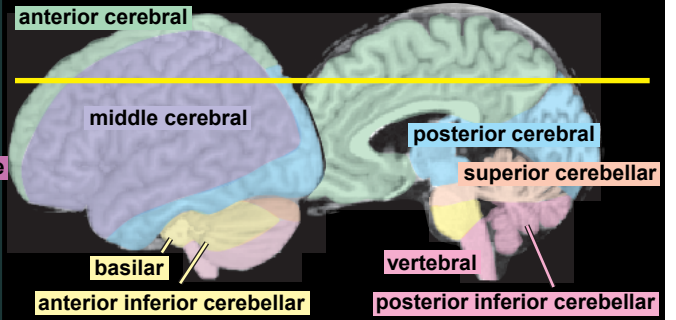
Arterial Territories & Major Tracts



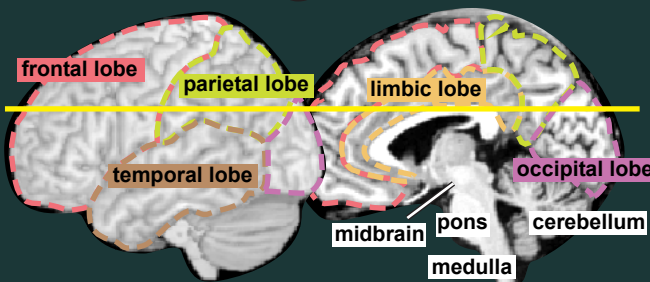
Cerebral Lobes & Major Regions



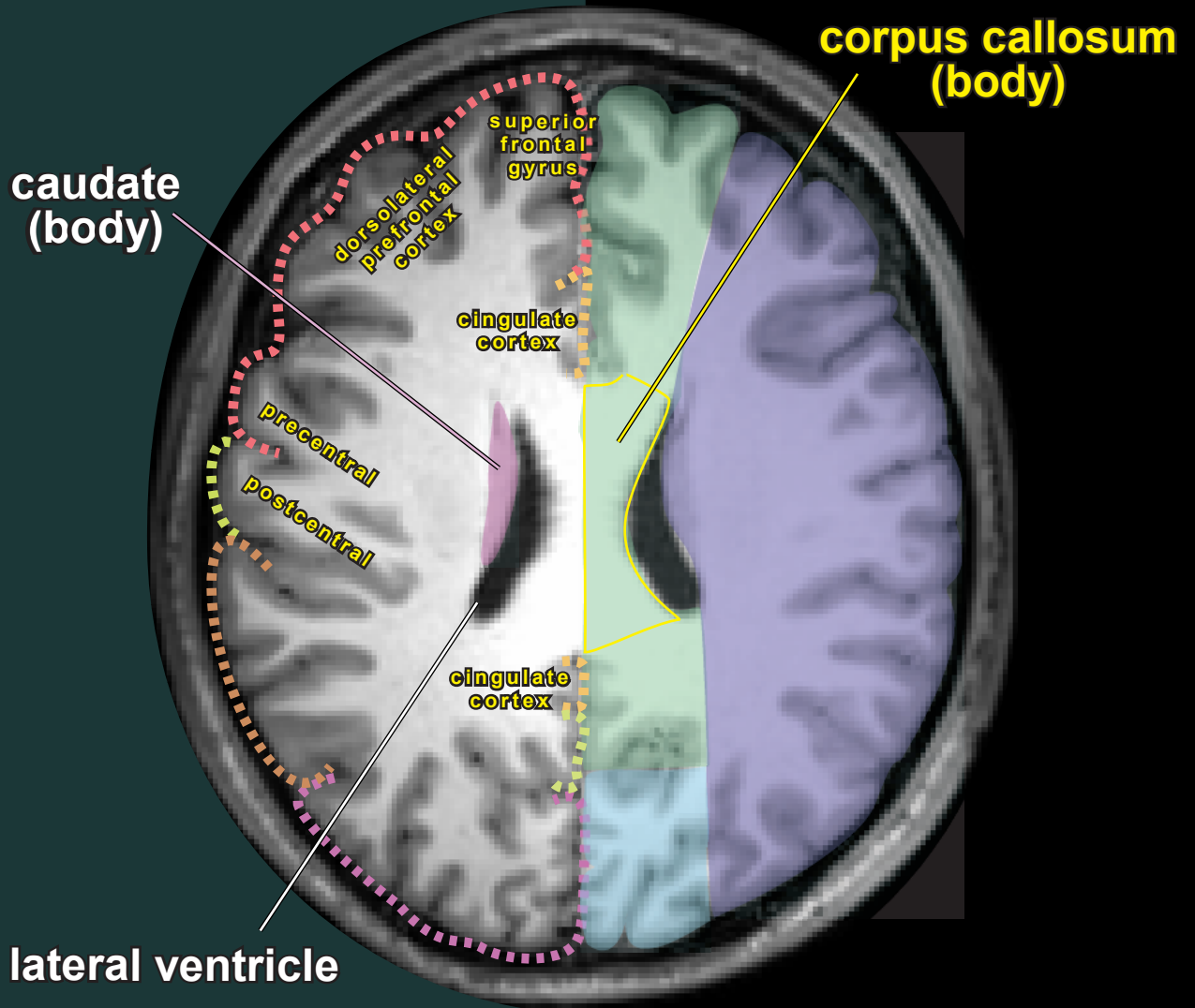
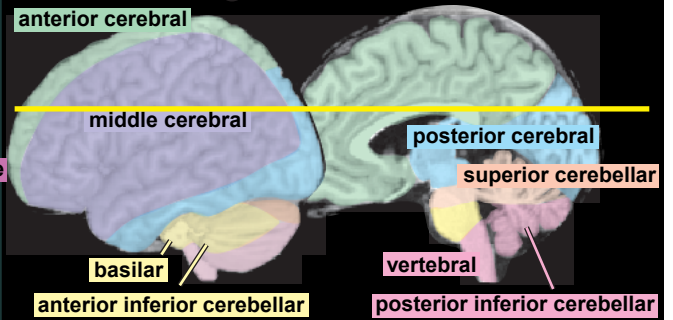
Arterial Territories & Major Tracts



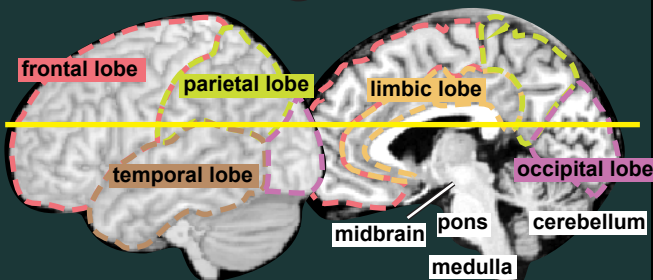
Cerebral Lobes & Major Regions



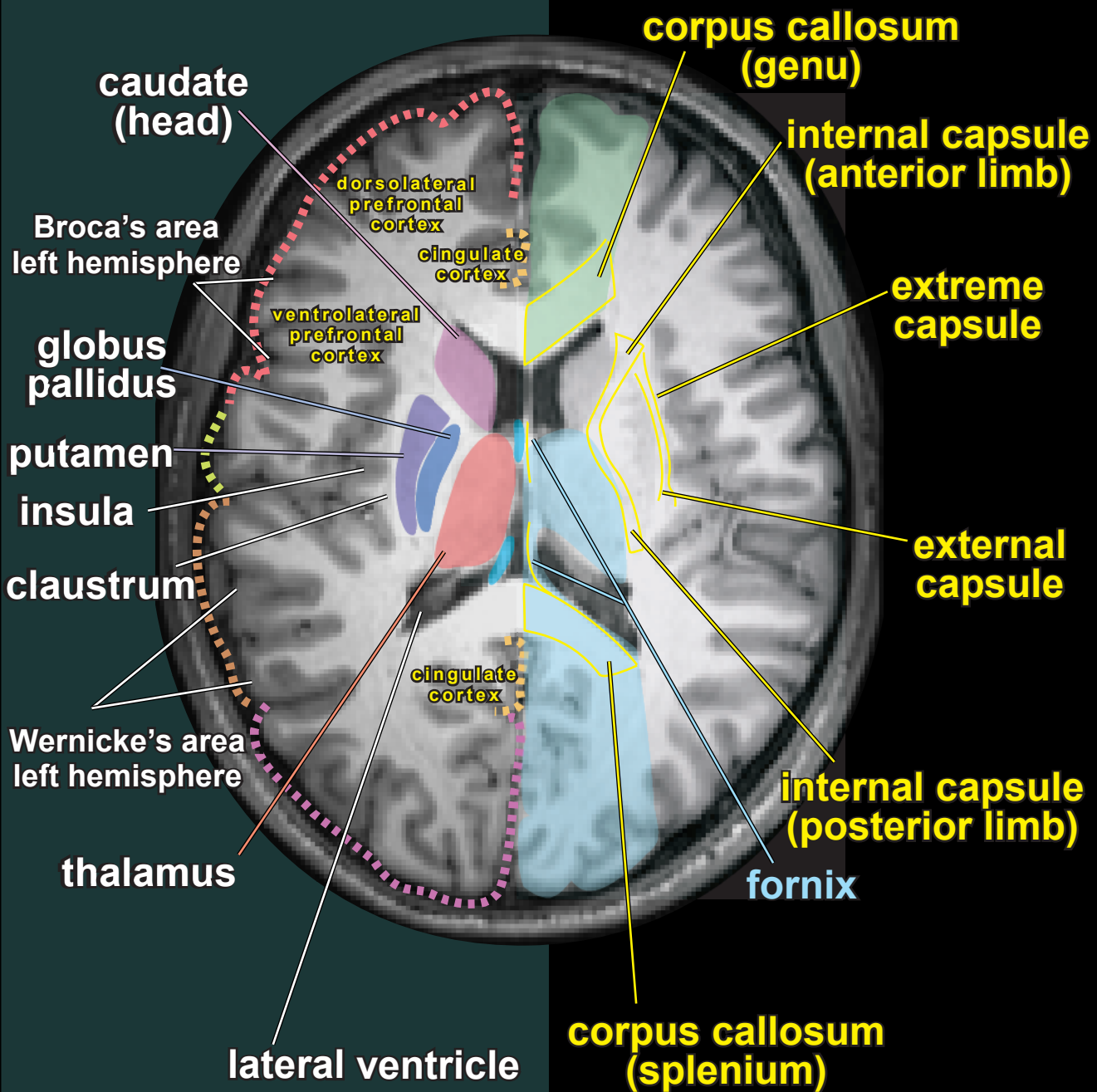
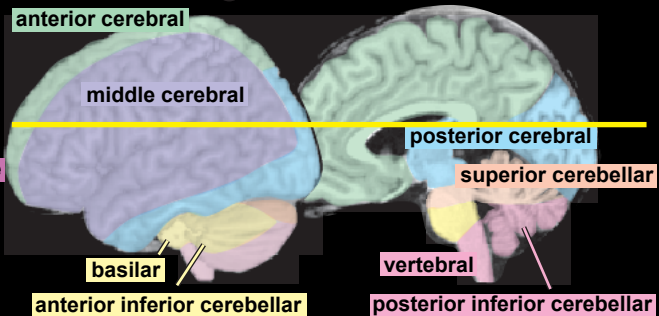
Arterial Territories & Major Tracts



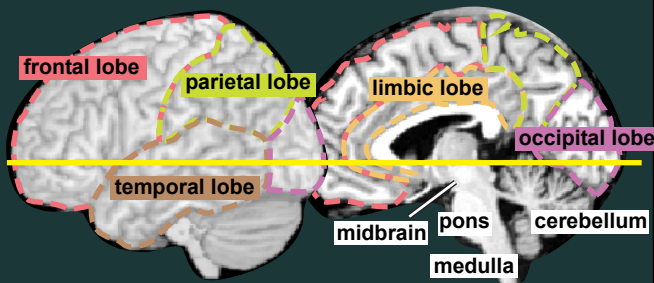
Cerebral Lobes & Major Regions



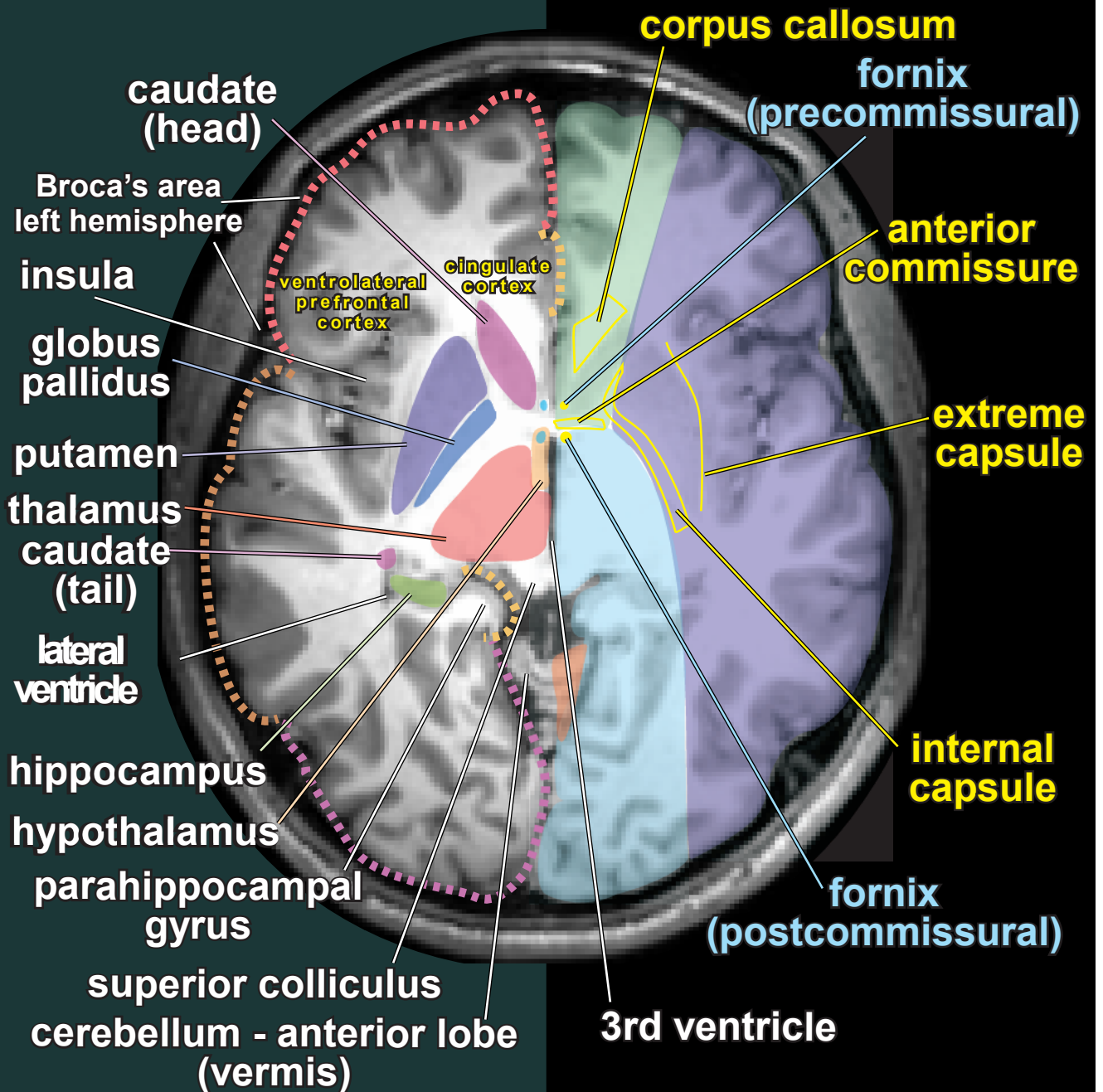
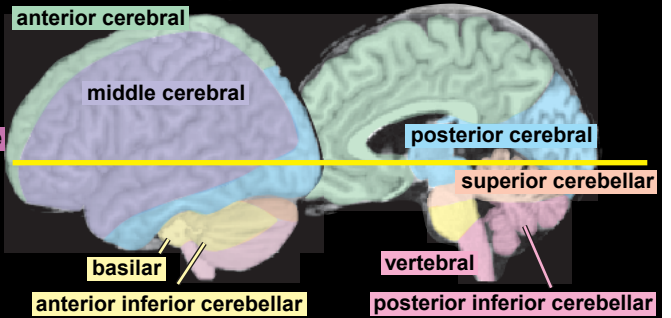
Arterial Territories & Major Tracts



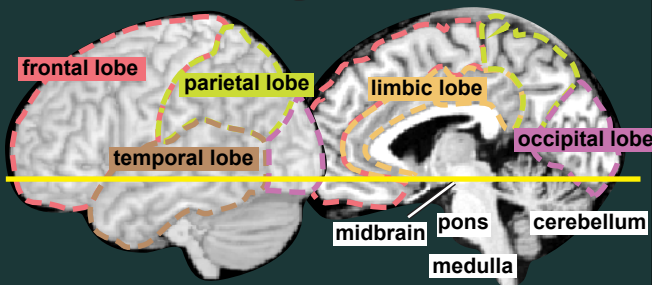
Cerebral Lobes & Major Regions



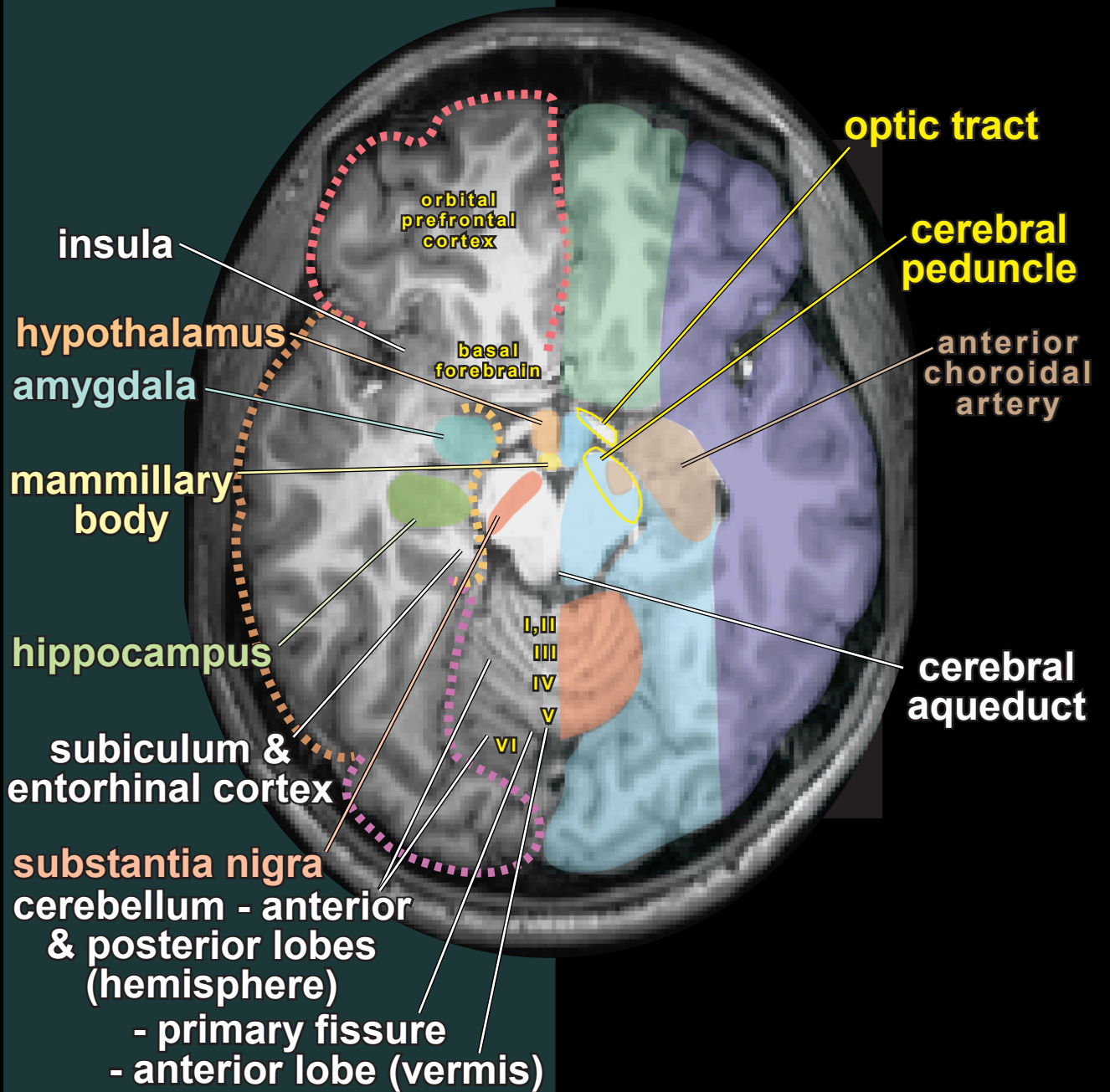
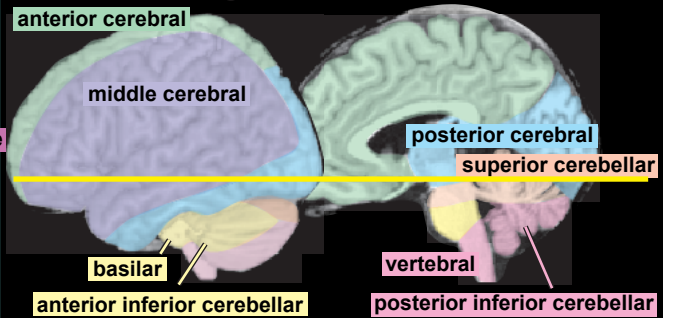
Arterial Territories & Major Tracts



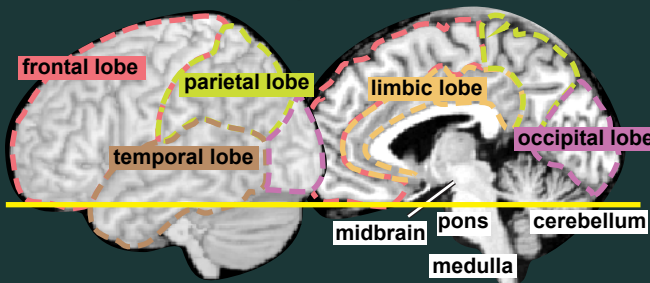
Cerebral Lobes & Major Regions



Arterial Territories & Major Tracts

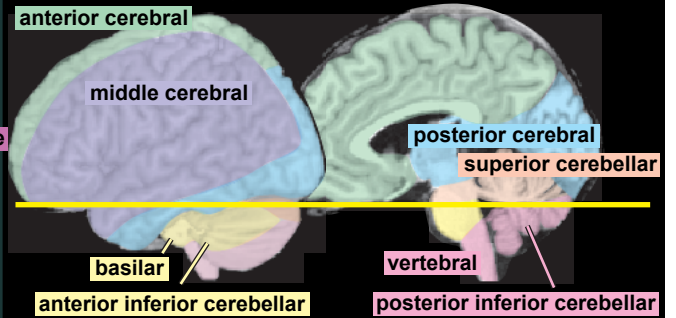


Cerebral Lobes & Major Regions



gyrus rectus

Arterial Territories & Major Tracts



amygdala

hippocampus

entorhinal cortex

cerebellum (hemisphere)

primary fissure

orbital prefrontal cortex

pons

anterior lobe

posterior lobe

internal carotid artery

anterior choroidal artery

superior cerebellar peduncle

4th ventricle